



Management of Subtrochanteric Fractures with Long PFN: Union Rates and Functional Results

Shakeel Ahmad¹, Rajinder Singh², Abdul Ghani³, Khalid Muzaffar⁴, Omeshwar Singh⁵

¹Registrar, Department of Orthopaedics, School of Medical Sciences and Research – Sharda University, Greater Noida, India; ^{2,3}Associate Professor, Department of Orthopaedics, G.M.C. Jammu, India; ⁴Senior Resident, Department of Orthopaedics, G.M.C. Jammu, India; ⁵Registrar, Department of Orthopaedics, School of Medical Sciences and Research – Sharda University, Greater Noida, India.

ABSTRACT

Introduction: The treatment of subtrochanteric fractures has evolved over a period of time, from conservative to extramedullary fixation to intramedullary fixation. The management of these fractures poses a significant challenge, the criteria for functional recovery becoming more and more exacting.

Aim of study: To assess union rates and functional status after long PFN in subtrochanteric fractures.

Material & Methods: A prospective study on adult patients with a follow up of 6 months was conducted at Orthopaedic department of Govt. Medical College Hospital, Jammu between June 2014 and May 2016. 40 patients above the age of 18 years with subtrochanteric fractures were included in the study. Patients were assessed clinically and radiologically on the 2nd postoperative day, at 4 weeks, 12 weeks and then between 6 months to 1 year depending upon the fracture union. At each follow up, functional evaluation of the patient was done.

Results: Majority of fractures (72.5%) united within 14 weeks. Full weight bearing was allowed by 12th week in majority (57.5%) of cases. Salwati & Wilson hip function score improved from 16 at discharge to 36 at 6 month follow up. As per Kyle's criteria, results achieved were Excellent/Good in 95% of cases.

Conclusion: Proximal femoral nail is an efficient device for the treatment of subtrochanteric fractures with high rate of bony union. The great majority of patients were provided with stable fixation, early mobilization, early rehabilitation and return to pre-fracture status.

Key Words: Subtrochanteric fractures, Long PFN, Union rates, Kyle's criteria

INTRODUCTION

The treatment of subtrochanteric fractures has evolved over a period of time, from conservative to extramedullary fixation to intramedullary fixation. The high incidence of delayed union, malunion and nonunion of fractures in this region has left conservative treatment; as advocated by DeLee et al¹ abolished in modern trauma care. This evolution in treatment modalities is due to unsatisfactory results achieved in these fractures due to medial comminution, high tensile forces active in this region² and various muscular deforming forces acting on the fracture fragments³ thus leading to high incidence of malunion and nonunion in these fractures and mechanical failure of the implant^{4,5}. The appropriate implant

for the internal fixation of subtrochanteric fractures remains debatable; and a multitude of different intra- and extramedullary devices for their surgical fixation have been advocated⁶⁻¹⁰. The advantage of closed reduction over open reduction cannot be over emphasized. Open reduction increases the risk of infection, soft-tissue devitalisation, and non-union and thus, poor functional results. Up to one half of the patients with subtrochanteric fractures may not regain their pre-fracture walking capacity, and independent living may no longer be possible¹¹. The management of these fractures poses a significant challenge, the criteria for functional recovery becoming more and more exacting. Subtrochanteric fractures are predisposed to complications from loss of position including coxa vara, rotational deformity or shortening,

Corresponding Author:

Dr. Shakeel Ahmad, Registrar, Department of Orthopaedics, School of Medical Sciences and Research – Sharda University, Greater Noida, India.
E-mail: bhat.shakib03@hotmail.com

Received: 19.03.2017

Revised: 02.04.2017

Accepted: 27.04.2017

non-union due to implant breakage or failure of bone substance and migration of fixation components¹².

We now report the results of clinical and radiographic follow-up of a series of subtrochanteric fractures treated with long proximal femoral nail (PFN – AO type design).

AIM OF STUDY

- To study union rates after long PFN in subtrochanteric fractures
- To assess functional status using Salwati & Wilson hip function scoring system after PFN in subtrochanteric fractures

MATERIAL AND METHODS

A prospective study on adult patients of both sexes with a follow up of 6 months was conducted at Orthopaedic department of Govt. Medical College Hospital, Jammu between June 2014 and May 2016. 40 patients above the age of 18 years with subtrochanteric fractures were included in the study. After clinical assessment and haemodynamic stabilization, patients were subjected for radiographs of Pelvis with both hips-AP view and full length thigh-AP and lateral views. Patients selected for study include:

Age - above 18 years

Sex - both males and females.

Patients with Seinsheimer types I –IV subtrochanteric fractures

Patients excluded from study include:

Polytrauma

Old complicated fractures.

Pathological fractures.

Seinsheimer type V subtrochanteric fractures.

Subtrochanteric fractures with associated neck/intertrochanteric/shaft fractures.

Patients with any contraindication for anaesthesia or surgery

All the patients were operated on a fracture table in supine position under image intensifier control using standard techniques. Patients were assessed clinically and radiologically on the 2nd postoperative day, at 4 weeks, 12 weeks and then between 6 months to 1 year depending upon the fracture union. At each follow up, functional evaluation of the patient was done to note the range of movements at the hip and knee, ability to walk, any pain, limp, residual shortening, deformities, wound condition and any residual complaint. Healing was judged by both clinical (pain & motion at fracture site)

and radiological (bridging callus filling the fracture site or trabeculations across the fracture site) criteria and functional outcome was reviewed according to the Salwati and Wilson hip function scoring system.

The final assessment was carried out at 24 weeks on the basis of radiological union and Salwati and Wilson hip scoring system.

Radiological assessment

All radiologically ununited fractures were graded as poor results.

Salwati and Wilson hip scoring system

The evaluation of results was based on following 4 parameters as Pain, Walking, Muscle power & motion, and Function. The results were classified as Excellent when the sum of scores was 32 or more, Good when it is 24 to 31, Fair when it is 16 to 23 and Poor when the score is 15 or less.

Pain

- 0 – Constant and unreliable, frequent strong analgesia
- 2 – Constant but bearable, occasional strong analgesia.
- 4 – Nil or little at rest, pain on activity.
- 6 – Little pain at rest, pain on activity.
- 8 – Occasional slight pain.
- 10 – No pain.

Walking

- 0 – Bed ridden
- 2 – Wheel chair
- 4 – Walking frame
- 6 – One stick, distance limited up to 400 yards
- 8 – One stick, long distance
- 10 – Unaided and unrestricted

Muscle power and Motion

- 0 – Ankylosing and deformity
- 2 – Ankylosing with good functional position
- 4 – Poor muscle power, flexion less than 60 degrees, abduction less than 10 degrees
- 6 – Fair muscle power, flexion 60 – 90 degrees, abduction 10 – 20 degrees.
- 8 – Good muscle power, flexion more than 90 degrees, abduction more than 20 degrees.
- 10 – Normal muscle power, full range motion

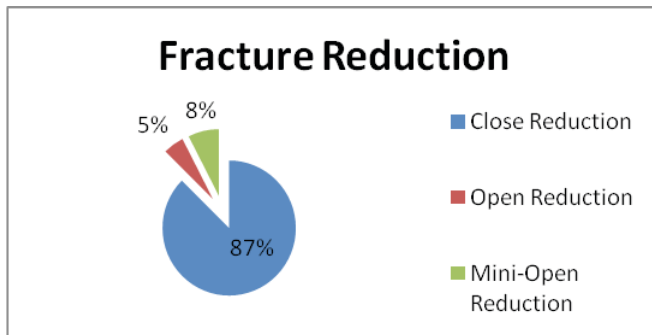
Function

- 0 – Bed ridden
- 2 – House bound
- 4 – Limited house work
- 6 – Most house work
- 8 – Very little restriction
- 10– Normal activity.

RESULTS

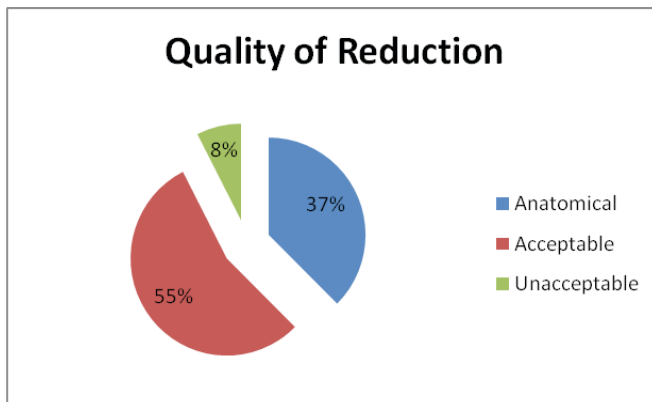
Total no. of patients in our study were 40; of which 25 were males and 15 females. Most of the patients belonged to age group of 41 – 50 years. The fractures were classified according to Seinsheimer classification¹³ (type II- 22 cases, type III – 14 cases, type IV – 4). In most of the cases(n = 23), the mechanism of trauma was a Road traffic accident, while as, in rest of cases(n = 17), Fall from height was responsible for trauma. 50% cases had associated injuries like fracture distal end radius, fracture calcaneum etc. Other characteristics noted are as mentioned below:

FRACTURE REDUCTION



From the chart, it is clear that majority of cases were managed by closed reduction (87%). 8 % cases required mini-open reduction.

QUALITY OF REDUCTION



In 92% of cases, reduction achieved was anatomical to acceptable. Whereas, in 8% of cases, reduction was not acceptable

NEED FOR BONE GRAFTING

None of the cases required bone grafting in our series. All fractures united spontaneously.

DURATION OF FRACTURE UNION (in weeks)

Duration of fracture union	No. of cases	Percentage (%)
10 – 12	16	40
13 – 14	13	32.5
15 – 18	8	20
≥ 18	3	7.5

Table 1 shows that majority of fractures united within 14 weeks(72.5%).

TOE TOUCH WEIGHT BEARING

Toe-touchweight bearing (days)	No. of cases	Percentage (%)
0 – 2 days	16	40
3 – 4 days	14	35
5 – 6 days	8	20
After 6 th day	2	5

Table 2 shows that in 75% of cases, we started toe touch weight bearing within 4 days.

PARTIAL WEIGHT BEARING

Partial weight bearing (weeks)	No. of cases	Percentage (%)
4 th week	16	40
5 th week	8	20
6 th week	11	27.5
7 th week	3	7.5
>7 th week	2	5

Table 3 shows that partial weight bearing was started at 4th week in majority of cases (40%).

FULL WEIGHT BEARING

Full weight bearing (weeks)	No. of cases	Percentage (%)
10 – 12 weeks	23	57.5
13 – 14 weeks	12	30
15 – 16 weeks	4	10
>16 weeks	1	2.5

Table 4 shows that we had allowed full weight bearing by 12th week in majority (57.5%) of cases.

GRADING OF HIP MOVEMENTS AT 24 WEEKS FOLLOW UP(HARRIS HIP SCORE GRADING)

ROM at hip	No. of cases	Percentage (%)
Excellent/good	32	80
Fair	6	15
Poor	2	5

Table 5 shows that excellent/good range of movement was achieved in majority (80%) of cases.

GRADING OF KNEE MOVEMENTS AT 24 WEEKS FOLLOW UP

ROM at knee	No. of cases	Percentage (%)
Good	34	85
Fair	5	12.5
Poor	1	2.5

Table 6 shows that good range of movement was achieved in 85% of cases.

PAIN AT HIP JOINT AT FINAL FOLLOW UP (SALWATI & WILSON HIP SCORING SYSTEM)

Pain Grade	No. of cases	Percentage (%)
No pain	32	80
Occasional slight pain	5	12.5
Pain on activity	3	7.5

Table 7 shows that 80% of cases reported no pain at 24 week follow up.

MUSCLE POWER AT FINAL FOLLOW UP(SALWATI & WILSON HIP SCORING SYSTEM)

Muscle power	No. of patients	Percentage (%)
Ankylosing in functional position	0	0
Poor muscle power	0	0
Fair muscle power	2	5
Good muscle power	32	80
Normal muscle power	6	15

Table 8 shows that 95% of patients attained good/normal muscle power by 6 months.

WALKING ABILITY OF THE PATIENT AT FINAL FOLLOW UP(SALWATI & WILSON HIP SCORING SYSTEM)

Walking ability	No. of cases	Percentage (%)
Bed ridden	0	0
Wheel chair	0	0
Walking frame	0	0

One stick, limited distance	1	2.5
One stick, long distance	3	7.5
Unaided & unrestricted	36	90

Table 9 shows that 90% of patients had attained normal walking ability.

Assessment as per Salwati and Wilson hip function scoring system:

At Discharge

Pain	4
Walking	4
Muscle power and motion	6
Function	2

At 24 week follow up

Pain	8
Walking	10
Muscle power and motion	8
Function	10

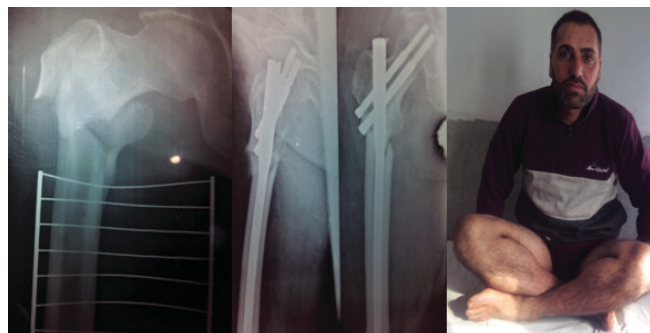Total score

At discharge	16
At 24 week follow up	36

RESULT ACCORDING TO KYLE'S CRITERIA

Results	No. of cases	Percentage (%)
Excellent	30	75
Good	8	20
Fair	2	5
Poor	0	0

Table 10 shows that we achieved Excellent/Good results in 95% of cases.



Pre-operative and Post-operative radiograph of 40 year old patient. Patient is shown as sitting cross legged at 6 month follow up.

DISCUSSION

Subtrochanteric fractures of the femur have peculiar anatomic and mechanical characteristics which poses problems in their management. Extramedullary fixation with plating has the potential disadvantages of extensive surgical exposure, severe soft tissue damage and blood loss, thus leading to problems of fracture union and implant failure. In addition, the eccentric plating is prone to fatigue breakage due to their mechanical load-sharing effect¹⁴. Allowing a minimally open approach, intramedullary nailing is closely linked to “biological internal fixation”, in addition to its mechanical benefits over plate fixation¹⁵.

The result of the reduction was considered acceptable in 55% of the patients and anatomical in 37% of patients. Poor reduction was noted in 8% of patients and it was associated with poor outcome. In SCHIPPER et al study¹⁶, reduction was good to acceptable in 96.2% of their patients and poor reduction was seen only in 2.9% of their patients.

Most of the cases in our series were managed by close reduction. However, in 8% of cases, mini-open reduction was required. Here, a small incision was made over the fracture site without extensive soft tissue dissection and using bone levers or bone clamps, fragments were held in reduced position till nailing was done. This is comparable with the studies of Boldin et al¹⁷(90.90% Close Reduction) and other studies done elsewhere.

Varus malreduction was the most common complication noticed in our series. This can be attributed to initial malreduction in which proximal fragment remained abducted. It is important that fracture should be reduced first, even if open reduction is required, before intramedullary nailing.

In this study, clinical union was achieved within 14 weeks in 72.5% of cases which is comparable to Smith et al series, who reported clinical union in 10.5 weeks and to Domingo et al series who reported union in 12 weeks. In our study, one patient had iatrogenic femoral shaft fracture which took 24 weeks to unite. In other series, the rate of fixation failure, femoral shaft fracture, and re-operation rate is high¹⁸ (12 %).

The mobilization strategy followed; touch down weight bearing was allowed within 4 days in 75 % of cases in whom there was little or no cortical comminution pre-operatively and in whom solid fixation was achieved, whereas it was allowed on 5th or 6th day in 20% of cases and after 6th day in 5% of cases where the fixation was not solid or there was gross comminution or due to iatrogenic fracture. This is consistent with the study of Smith et al, who allowed touch down weight bearing on 2nd postoperative day in 71.5% of cases and delayed in 28% of cases.

In our series, average time to full weight bearing was 14 weeks in 87.5% of cases which is late as compared to the series by

Smith et al who started full weight bearing by 6.7 weeks. Walking and squatting ability was completely restored in each case at follow-up examination 6 months postoperatively.

Pain during walking was reported in 7 cases. Physical examination revealed that the pain was either located at the point around the greater trochanter or due to protrusion of neck screws rather than at the fracture site. Radiographic examination showed that the proximal part of the nail had protruded above the tip of the greater trochanter too much because of the relative short stature of these patients. It was the friction between the protruded proximal nail and its surrounding soft tissues that had led to the walking pain. No case of limping due to shortening of the affected leg was reported in our series.

In this study, Good range of motion at knee was seen in 85% of cases, whereas, range of motion was reported as Fair in 12.5% of cases. In a series by Weiss et al, moderate loss of range of motion was reported in 6.2% of cases. In this study, incidence of loss of range of motion at knee was more, due to the poor compliance of patients to physiotherapy.

It is recommended that aggressive rehabilitation programme including partial or full weight-bearing initiated at suitable time after operation under the guidance of professional physical therapists should be done. We believe that delayed partial weight-bearing after surgical operation and the relative narrow canal of the femoral isthmus might decrease the complications such as rotational malalignment, limb shortening and implant failure in this series, even if distal interlocking with only 1 screw was performed.

In studies on the treatment of injuries and diseases of the hip, the outcome is frequently reported using basic measures such as range of motion, fracture healing and the need for revision surgery. Additionally, the functional outcome is often reported using region-specific outcome instruments such as Charnley’s numerical classification¹⁹. Two major disadvantages of many of these specific instruments is that they do not allow a comparison of the outcome in patients with different or multiple injuries/diseases of the musculoskeletal system and they are not self-reported, i.e. they do not report the outcome from the patients’ own perspective.

Previous studies indicate that patients with impaired cognitive function have an increased risk for general as well as fracture-related complications²⁰, problems in assimilating rehabilitation²¹, prolonged hospital stay, poor long-term outcome and an increased mortality rate²². Our study was consistent with these findings.

Excellent functional results were obtained in 75% of cases and 20% of cases reported Good results, 5% as Fair result. This is consistent with the observations of Raj et al and Bergman et al, who reported excellent to good results in 84% and 90% of cases, respectively.

In this study, rate of union was 100% and no case required bone grafting. Removal of the distal locking bolt for dynamizing the nails to improve bone union was not made as it was esteemed unnecessary in any case.

CONCLUSION

Proximal femoral nail is an efficient device for the treatment of subtrochanteric fractures with high rate of bony union provided optimal reduction of the fracture and good positioning of the nail and screws is achieved. The great majority of patients were provided with stable fixation, early mobilisation, early rehabilitation and return to pre-fracture status.

ACKNOWLEDGEMENT

We are thankful to all those staff members of the institute who participated in the study. Authors acknowledge the immense help received from the scholars whose articles are cited and included as references in this manuscript. The authors are also grateful to authors / editors / publishers of all those articles, journals and books from where the literature for this article has been reviewed and discussed.

Ethical Clearance: Taken from the institution.

Informed Consent: Taken individually.

Financial support: Nil

Conflict of Interest: The authors have declared that no conflict of interest exists.

REFERENCES

- DeLee JC, Clanton TO, Rockwood CA Jr. Closed treatment of subtrochanteric fractures of the femur in a modified cast-brace. *J Bone Joint Surg Am* 1981;63:773-9.
- Koch JC. The laws of Bone architecture. *Am j anat* 1917; 2:177.
- Campbell's operative orthopaedics. 12th edition, Vol 3, 2751 – 2752, 2013.
- Haidukewych GJ, Berry DJ. Non-union of fractures of the Subtrochanteric region of the femur. *Clin Orthop Relat Res* 2004;419:185-8.
- Broos PL, Reynders P. The use of the unreamed AO femoral intramedullary nail with spiral blade in nonpathologic fractures of the femur: experiences with eighty consecutive cases. *J Orthop Trauma* 2002;16:150-4.
- Blatter G, Janssen M. Treatment of subtrochanteric fractures of the femur: reduction on the traction table and fixation with dynamic condylar screw. *Arch Orthop Trauma Surg* 1994;113:138-41.
- Hotz TK, Zelweger R, Kach KP. Minimal invasive treatment of proximal femur fractures with the long gamma nail: indication, technique, results. *J Trauma* 1999;47:942-5.
- Tornetta P III. Subtrochanteric femur fracture. *J Orthop Trauma* 2002;16:280-3.
- Siebenrock KA, Muller U, Ganz R. Indirect reduction with a condylar blade plate for osteosynthesis of subtrochanteric fractures. *Injury* 1998;29Suppl 3:C7-C15.
- Ruff ME, Lubbers LM. Treatment of subtrochanteric fractures with a sliding screw-plate device. *J Trauma* 1986;26:75-80.
- Koval KJ, Skovron ML, Aharonoff GB, Zuckerman JD. Ambulatory ability after hip fracture. A prospective study on geriatric patients. *Clin Orthop Relat Res* 1995;310:150-9.
- Roberto U, Velasco, MD; and Thomas H. Comfort, MD. Analysis of treatment problems in sub-trochanteric fractures of the femur: *The Journal of Trauma*, Vol. 18, No. 7, 513 – 523, 1978.
- Seinsheimer, F., III: Subtrochanteric fractures of the femur. *J Bone Jt. Surg.*, 60-A: 300-306, 1978.
- Lunsjo K, Ceder L, Thorngren KG, Skytting B, Tidermark J, Burntson PO. Extramedullary fixation of 569 unstable intertrochanteric fractures. *Acta Orthop Scand* 2001;72:133-40.
- Brien WW, Weiss DA, Becker V Jr, Lehman T. Subtrochanteric femur fractures: a comparison of the Zickel nail, 95-degree blade plate, and interlocking nail. *J Orthop Trauma* 1991;5:458-64
- Schipper I B et al Treatment of Unstable trochanteric fractures :*JBJS* 2004; 86 B : 86 – 94.
- Christian Boldin, Franz J Seibert, Florian Fankhauser: “The proximal femoral nail (PFN)—a minimal invasive treatment of unstable proximal femoral fractures. *Acta Orthop Scand* 2003; 74(1): 53-58.
- Menezes DF, Gamulin A, Noesberger B. Is the proximal femoral nail a suitable implant for treatment of all trochanteric fractures? *Clin Orthop Relat Res* 2005; 439:221–7.
- Charley J. The long-term results of low-friction arthroplasty of the hip performed as a primary intervention. *J Bone Joint Surg Br* 1972;54:61-76.
- Strömberg L, Lindgren U, Nordin C, Ohlen G, Svensson O. The appearance and disappearance of cognitive impairment in elderly patients during treatment for hip fracture. *Scand J Caring Sci* 1997;11:167-75.
- Huusko TM, Karppi P, Avikainen V, Kautiainen H, Sulkava R. Randomised, clinically controlled trial of intensive geriatric rehabilitation in patients with hip fracture: subgroup analysis of patients with dementia. *Bmj* 2000;321:1107-11.
- Svensson O, Strömberg L, Ohlen G, Lindgren U. Prediction of the outcome after hip fracture in elderly patients. *J Bone Joint Surg Br* 1996;78:115-8.